Preliminary experience with the use of *pedicle screws* and *flexible bar* for the treatment of lumbar spinal diseases.

Luciano Mastronardi
Chief of Neurosurgery
San Filippo Neri Hospital
Roma, Italy

Azienda Complesso Ospedaliero
San Filippo Neri
Ospedale di rilievo nazionale e di alta specializzazione

MIG-Roma

Starting point

- The elimination of motion produced by rigid spinal fixation may have consequences:

1. overloading juxtaposed spinal motion segments (*functional consequences*);
2. leading to degenerative changes at adjacent levels (*organic consequences*).

Background

- Adjacent segments degenerative disease to instrumented levels has sparked increasing interest over the last years.

- In order to prevent degenerative disc changes at segments adjacent to fused levels several techniques have been developed, including pedicle screw fixation with flexible bars (*semi-rigid dynamic rods*).

Our “flexible” fixation series

- 36 cases *(10/2009 - 12/2013)*

- 16 segmental instability with LowBackPain
- 11 severe lumbar stenosis
- 2 stenosis with instability
- 4 A1-A2 lumbar fractures (pts with degenerative disease)
- 2 mild listhesis with instability

Osteoporosis

- The incidence of screw loosening increases significantly in patients with severe osteoporosis.

- Biomechanical tests have shown that a pedicle screw that expands within the vertebrae body can substantially improve fixation in the presence of osteoporotic bone.

Osteoporotic series *(5/2012 – 12/2013)*
Material & Methods

- 15 patients with lumbar diseases
  - 13 Stenosis +/- Degenerative Lysthesis
  - 2 Traumatic Fractures

- pre-operative DEXA bone mineral density scan (BMD) mean T-score of -2,5

- Adjacent Segment Disease in all cases

Osteoporotic series
Typical case

Technique

- decompression: laminectomy and/or foraminotomy
  (except for the fractures)
- two or three-level stabilization with

expandable pedicular screws (*Osseoscrew*)

&

semi-rigid dynamic rods (*Isobar Evolution*)

Technique:
Osseoscrew + 2-level Isobar Evolution (Scient'x Aphatec)

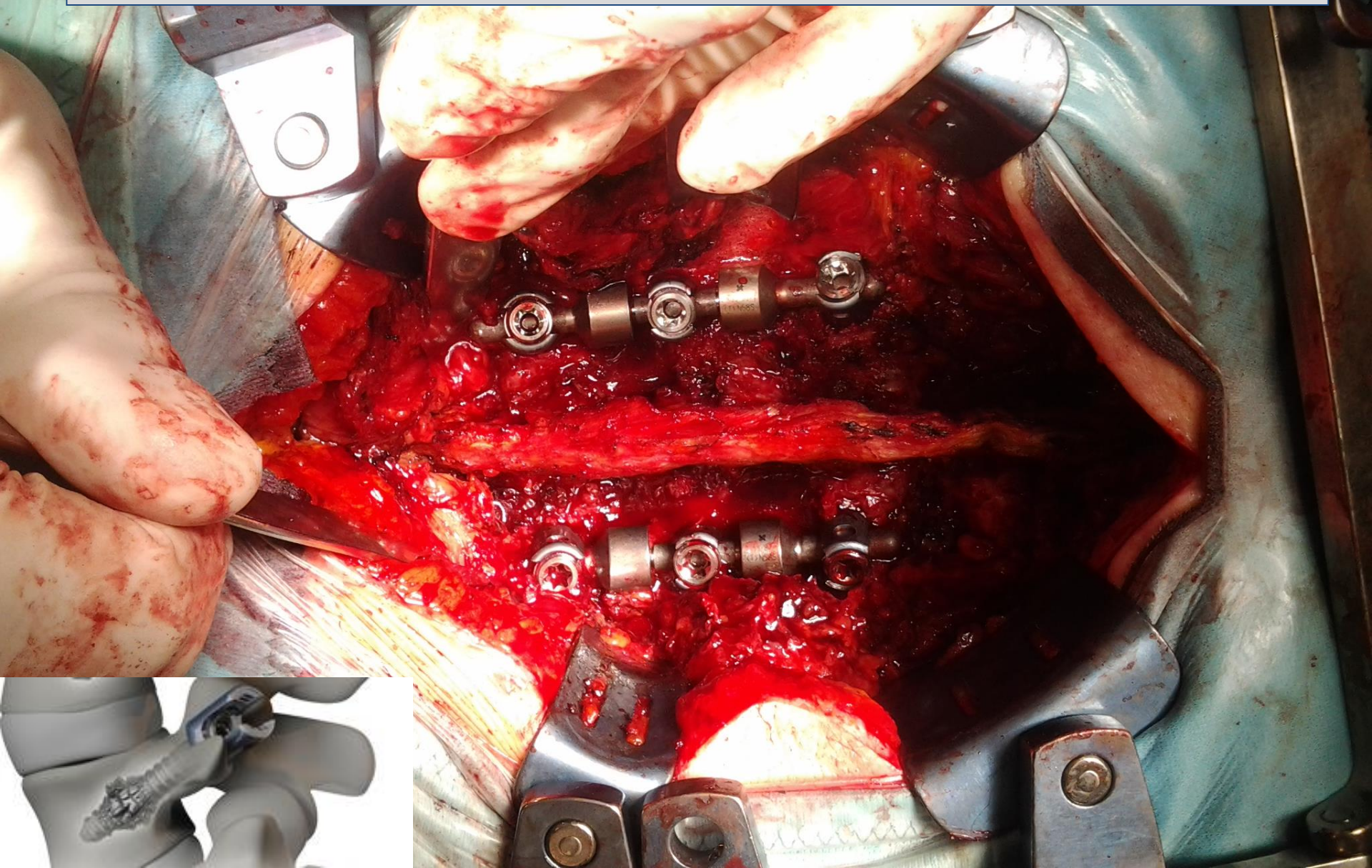

Complications

- Two cases of incidental CSF leakage (unrelated to the devices), both in patients with severe stenosis and lysthesis, healed after prolonged subfascial drainage

Results

in 17 cases with
7-12 months clinical-radiographic followup

- VAS &ODI markedly **improved** in all cases.
- Two cases had recurrent low back pain
- No instances of screw loosening, or breakage, or pull-out of the screws
- Good screw-bone interface
- Until now, prevention of degenerative disease above the fixed segments

Final Considerations

- The raise of intradiscal pressure

  at the adjacent levels consecutive to a rigid instrumented segment can be

  reduced

  when the rigid construct is augmented with a flexible stabilization device, using

  semi-rigid dynamic rods.

Final Considerations

- Augmentation with

  titanium expandable screws

  may represent an advisable solution in pts with documented severe osteoporosis.

Proposal

- Multicenter study group on the efficacy of Osseoscrew + Isobar Evolution implant in osteoporotic patients with:

1. Degenerative stenosis +/- listhesis
2. LBP for degenerative/iatrogenic instability
3. Mild symptomatic spondylolisthesis
4. A2 lumbar fracture (open or mini-invasive)
5. Other?

Conclusion

- The flexible lumbar constructs might have a possible protecting role preventing the occurrence of degenerative disc changes at the adjacent segment also in osteoporotic patients.